



Multiple Trauma with Severe Brain Injury Cause by Impression Fracture: Case Report and Literature Review

Ahmad Hannan¹, Khamim Thohari², Khofifah Dwi Oktaviani³, M. Dedi Dermawan³, Mohammad Hasan³, Muhammad Hanun Mahyuddin³

¹ Department Orthopedic Surgery Faculty of Medicine, Muhammadiyah Surabaya University/RSUD dr. Soegiri, Lamongan

² Department Neurosurgery Faculty of Medicine, Muhammadiyah Surabaya University/RSUD dr. Soegiri, Lamongan

³ Faculty of Medicine, Muhammadiyah Surabaya University/RSUD dr. Soegiri, Lamongan

Article Info	Abstract
<p>Article history: Received 30 June 2022 Revised 28 July 2023 Accepted 28 July 2023 Available online 30 July 2023</p> <p>Keywords: multiple trauma; brain injury; impression fracture</p> <p>Correspondence: hannanortho@gmail.com</p> <p>How to cite this article: A Hannan, K Thohari, KD Oktaviani, MD Dermawan, M Hasan, MH Mahyuddin. Multiple Trauma with Severe Brain Injury Cause by Impression Fracture: Case Report and Literature Review. MAGNA MEDIKA Berk Ilm Kedokt dan Kesehat. 2023; 10(1):117-128</p>	<p>Background: Multiple trauma, one trauma caused by a substantial traumatic force, involves many organs and tissues. AIS and ISS are scoring for multiple trauma diagnoses and classifications. This Case Report discusses multiple trauma patients with Severe Brain Injury caused by Impression Fracture with open fracture in regio cruris sinistra and close fracture femur sinistra.</p> <p>Case presentation: The following is a case report of a 63-year-old female patient who came to the emergency room of Soegiri Lamongan with decreased consciousness due to a traffic accident. The mechanism of injury was that the patient's head hit the chair and the driver's side of the car pillar, and the patient's legs were pinched by the car seat. Since the 25-year-old patient has a history of uncontrolled diabetes mellitus but regularly takes anti-diabetic drugs (OAD). The patient was diagnosed with multiple trauma, severe brain injury, and suspected DAI with open fracture grade 3A middle 1/3 tibia and close fracture middle 1/3 distal femur.</p> <p>Conclusion: Multiple Trauma has a lousy prognosis. The most important from Multiple trauma management is prehospital management. Additional Severe Brain Injuries make the diagnosis worse.</p>
<p>2023 MAGNA MEDIKA: Berkala Ilmiah Kedokteran dan Kesehatan with CC BY NC SA license</p>	

INTRODUCTION

Multiple trauma leading to simultaneous trauma or sequentially trauma from two or two parts of tissue that affect the organ above because of the exact mechanism of injury, one of leading to The evaluation of severe multiple trauma depends on *Abbreviated Injury Scale* (AIS) and *Injury Severity Score* (ISS), which the $ISS \geq 20$ that define as severe multiple trauma¹.

Multiple trauma mostly happens in traffic accidents, falls from high places, and so on. - Multiple trauma is complex and involves many systems, organs, and sites, including severe organs and tissue damage, most of them accompanied by shock, secondary infection, Multiple Organ Failure (MOF), etc. Patient with multiple trauma has an accidental injury, complex injury, high mortality, and lousy prognosis, which often require multidisciplinary collaboration and joint care, which are significant challenges for medical workers at all levels of the hospital in clinical work. To further increase the success rate of treatment and prognosis on the patient with multiple trauma and reduce the burden of social and family medical care, this paper reviews research advances in the diagnosis and treatment of multiple trauma.

In this case report, we will discuss a multiple trauma patient with brain injury due to an impression fracture with an open fracture of the left cruris region and a closed fracture of the left femur.

CASE PRESENTATION

A 63-year-old woman came to the dr. Soegiri Lamongan with a decrease in consciousness because of traffic accidents. The patient was

transferred from Karang Rembang Babat Hospital with a lesion in the eyelids and pain in the booth of the foot. The patient had been unconscious post the accident and awake when she arrived at Karang Rembang Hospital. The patient is a traffic accident victim in road toll Tuban-Widang KM 19-20 when he was driving a car and was hit by other cars from another direction. of injury the patient's head hit the chair, and the driver's side of the car pillar and the patient's legs were pinched by the car seat. He had a history of uncontrol diabetic mellitus for 25-years-old, but he was continuously drinking Oral anti-diabetic (OAD). He did not have a history of hypertension.

In a primary survey, we found a patent airway (A), no snoring, gargling, and crowing in breathing (B). Circulation, the patient's acral was found to be cold with CRT >2 seconds, and there was active bleeding. We found on Disability (D) Examination. Examination of the head, neck, thorax, and abdomen was normal. On examination of the extremities, he found cold acral with bruises and edema of the lower extremities.

After the patient was stable, we checked the vital sign, Blood Pressure 122/67 mmHg, heart rate 184x/minute regular, respiration rate 23x/minute, temperature 36,5°C, last the saturation of the perifer oxygen (SpO₂) 98% with nasal cannula four lpm.

Localized examination revealed that faciei regio looked like ripped om frontalis dextra passing by regio orbita with seven stitches and bruises on orbita (Figure 1). In regio genu dextra et sinistra, we found deformity, bruises, crepitation, tenderness, and limited Range of Motion.

On the cruris region, there is enormous skin damage and deformity, but splints and bandages were installed (Figure 2). Cruris distal Artery Examination revealed pulsation +, pale acral, tenderness, and warm palpable skin. The patient got infusion PZ 2000cc/24 jam, Metamizole injection (Antrain) 3 x 1g, Ranitidine injection 2 x 50mg, Ceftriaxone Injection 2 x 1g Citicolin Injection 3 x 500, and Tetanus Profilaction injection with *Human Tetanus Immunoglobulin* 250 IU (Tetagam).

Laboratorium examination results are listed in Table 1. Active bleeding causes a decrease in hemoglobulin, with a score of 9.4 dl/ml. GDA patients still high indicate uncontrolled diabetic mellitus.

In X-ray radiologist examination, the sinistra femur found a close fracture in 1/3 distal. Furthermore, in the cruris, we found an open fracture of 1/3 medial tibia (Figure 3). By Gustilo–Anderson's grading, our patient belongs to the 3A grade.

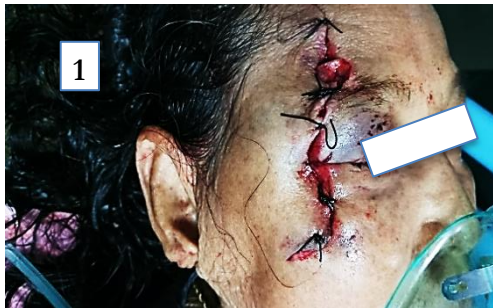

Figure 1. Regio Faciei Patient examination. Found a laceration in the right eyelids and a hematoma in the right eye.

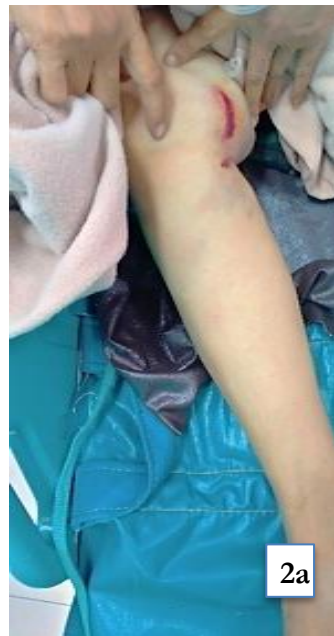

Figure 2 a,b. Local Examination on regio cruris sinistra patient. We found open fracture on cruris regio.

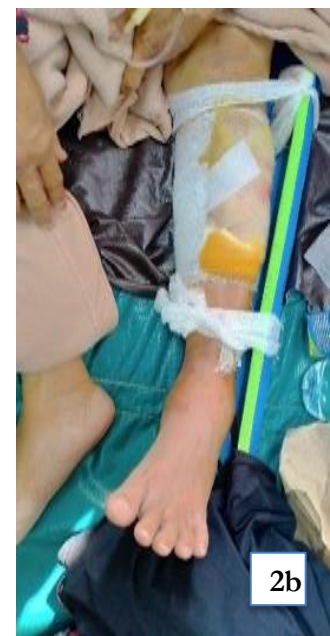

Table 1. Laboratorium Examination Result

	Normal Value	Result
Hemoglobin	L:13,2-17,3 P:11,7-15,5	9,4
Leukosit	3.600-11.000	26.700
BSR	10-20/jam	100-115
PCV	L:40-52% P: 35-47%	28,6
Trombosit	150.000-440.000/ul	319.000
Albumin	3,4-4,8 mg/dl	2,9
BSN	<200	276

*BSR: Blood Sedimentation Rate; PCV: Pack Cell Volume; BSN: Blood Sugar Nuchter

Examination without contrast found a picture of compression fracture on Os. Frontal Dextra with a hippo-intense lesion in a contralateral lesion of compression fracture, meaning there is contrecoup injury. The patient also had Ventriculomegaly, and we suspect Diffuse Axonal Injury (DAI) (Figure 4).

The patient was diagnosed with Multiple trauma with Severe Brain Injury, DAI, and open fracture grade 3A in 1/3 middle of the tibia and a close fracture in the middle of 1/3 distal femur.

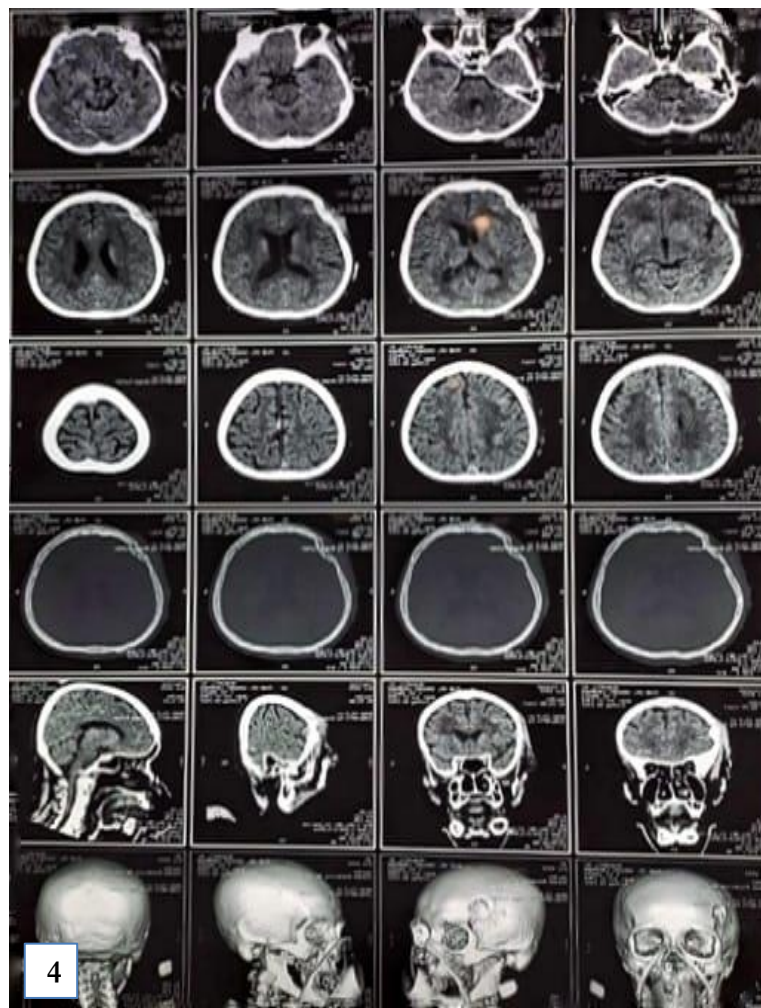
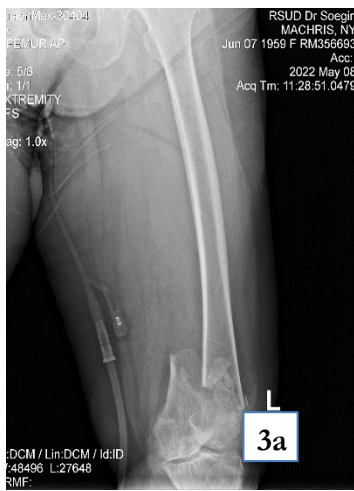

Figure 3 a,b. Radiologis Picture on regio femur sinistra (a) and regio ruris sinistra (b); Figure 4. Head MRI

DISCUSSION

Currently, it is generally accepted that the diagnosis of multiple trauma is as follows: (1) the presence of a severe injury with AIS ≥ 3 points at ≥ 2 different anatomic locations, and in combination with the following pathological parameters: systolic blood pressure ≤ 90 mm Hg; Glasgow Coma Scale (GCS) ≤ 8 ; Base excess (BE) ≤ -6 mmol/L; International standard ratio (INR) ≥ 1.4 or activated partial thromboplastin time (APTT) ≥ 40 seconds³. The Committee of the Trauma Emergency and Multiple Trauma Group of China defines the diagnosis of multiple trauma as follows: trauma caused by mechanical injury factors that, at the same time, two or more parts of tissues and organs are injured at the same time or sequentially. Any of these injuries, even if only present, can be life-threatening. As an independent diagnosis, multiple injuries must follow the principles of injury diagnosis (location of injury, nature of injury), injury complications, and diagnosis of accompanying disease⁴.

The Abbreviated Injury Scale (AIS) is currently recognized as a method of assessing injury severity based on anatomic injuries and is commonly used worldwide, compiled by the American Association for the Promotion of Motor Vehicle Medicine (AAAM). According to the degree of injury in the body area, it divides each damaged area into 6-grade sequences. The ISS originates from the AIS and divides the body into six areas (head and neck, face, chest, abdomen, legs, pelvis, and body surface). Each region has an AIS score, with a score of 1 to 6 points. One mild, two moderate, three severe, four severe, five critical, and six extreme (currently untreatable).¹

The ISS score is the sum of the squares of the highest AIS scores in the body's three severely damaged areas. The ISS score range is 1~75, with ISS < 16 as a minor injury, ISS ≥ 16 as a serious injury, ISS ≥ 20 as a severe injury, and ISS > 50 as a severe injury; the survival rate is very low.¹

In recent years, many studies have shown the relationship between ISS scores and the prognosis of patients with multiple trauma. The ISS score can be used as a reference index to predict the condition and prognosis of patients with severe multiple injuries⁵. The higher the ISS score, the more serious the condition and the worse the prognosis of patients with multiple injuries⁵. Score ISS 16 is an independent risk factor for death in patients with multiple injuries². The patient's AIS and ISS scores are reported in Table 2. The patient had a total AIS score of 11 and an ISS score of 45, indicating that the patient's multiple trauma was included in the severe category but did not increase the risk of death.

Although the AIS and ISS can be used to classify the severity of injury, the modified trauma score (RTS) is physiological. Although AIS and ISS can be used to classify the severity of the injury, the Improved Trauma Score (RTS) is a physiological score that can be calculated by the sum of systolic blood pressure, respiratory rate, and GCS scores assessed before admission to the hospital when the patient was not aware of the trauma experienced by the patient. RTS score < 11 is a severe injury. RTS > 11 is classified as a minor injury. It has been reported that the RTS is superior to the ISS in predicting mortality from multiple injuries.

Table 2. AIS and ISS Patient Score

Trauma	Score
A) Open Fracture impression in the Frontal	5
B) Open Fracture grade 3A in 1/3 middle of sinistra cruris	4
C) Close Fracture in 1/3 distal femur sinistra	2
ISS: $A^2 + B^2 + C^2$	45

Table 3. AIS-Head Patient Score

Trauma	Score
Cerebrum ; DAI	4
Cerebrum ; EDH	3
Cerebrum; intraventricular bleeding	2

The American Trauma Society compiled in 1983 that the Trauma and Injury Severity Score (TRISS), ISS, and RTS, derived by the AIS, could be used to calculate the comprehensive TRISS score, which has a higher predictive value for mortality⁷. TRISS is an international standard for predicting outcomes and evaluating treatment in trauma scoring systems, which is widely used in trauma research. However, the TRISS system has some drawbacks, such as lower evaluation of severity, low energy injury patients, failure of total RTS, failure to account for patient gender and impact of pre-injury health status on trauma outcome.

AIS scores in brain trauma patients have different assessments. In 2005, the AIS-Head Score was revised to provide more detailed information about head injuries and to reflect their clinical severity better, but the impact of these changes is largely unknown⁸. In the case we reported, the AIS-Head scores are reported in Table 3. The patient's total AIS-Head score is 9

Prehospital first aid in multiple trauma is crucial in multiple trauma care. The goal is to

save lives and reduce disability⁷. Therefore, prompt and appropriate treatment for multiple trauma is a fundamental requirement of emergency management for multiple trauma. Patients with multiple trauma have a poor prognosis and high mortality and thus require multidisciplinary cooperation and general care. Currently, there are two main modes of care in the world: (1) The French-German model: is characterized by "sending hospital to the patient," which emphasizes on-site care for patients with multiple injuries. (2) The American-British model: characterized by "taking the patient to a hospital," which emphasizes the rapid transportation of patients with multiple trauma¹. The two models differ in the treatment concept, but both emphasize the smooth and effective linkage of medical information in the prehospital care process.

Professor Jiang Baoguo's team, according to China's national conditions and current situation, put forward the core concept of several injury treatment norms, including: "1 region, two links, three teams." In this case, "1 region", i.e., a prominent local third-class

hospital in collaboration with local government to establish a regional trauma care center to standardize the process of prehospital and in-hospital care; The second is the "2 links" to strengthen the exchange of information between prehospital care and in-hospital care, between emergency departments and their respective specialties. The third is the "3 teams", namely the prehospital first aid team, the hospital emergency team, and the specialist care team. The three teams are closely related and work together with each other to make patients with multiple traumas get timely and appropriate care.

Integrated trauma care mode is a kind of treatment mode that integrates prehospital first aid, hospital emergency, intensive care, stable care, rehabilitation after treatment, and so on. This model requires a complete maintenance system. First, the hospital must establish a treatment team consisting of emergency, orthopedic, neurosurgery, cardiothoracic surgery, general surgery, and other relevant departments. A deputy chief physician should lead team members from each department. And standby 24 hours a day. Second, strengthen the relationship between prehospital care and hospital emergencies, facilitate prehospital physicians to understand the patient's situation at any time, and carry out appropriate prehospital care preparation work so that patients in the "golden period" receive adequate treatment. Finally, the local government should divide the medical area, establish a regional treatment system, and shorten the time from the injury site to the hospital ¹⁰.

The prehospital first aid team performs emergency care to patients at the scene and transmits the situation on the spot to the

hospital via communication equipment. The doctor in the hospital notifies the relevant department staff to prepare according to the condition of the patient's injury and starts the green channel at the same time.¹

Once the patient arrives at the emergency department, the prepared emergency care team immediately performs the assessment and resuscitation of the injured patient's organs. According to injury control theory, patients who need emergency surgery should actively improve the relevant preoperative preparation and carry out emergency surgery; if they do not require emergency surgery, they will undergo deterministic surgery once their condition stabilizes. This treatment model is applied in several large tertiary hospitals in China.¹

Xiao Yongjian believes implementing this model depends on the cooperation of various units and departments, especially the connection between the prehospital and the hospital. This model involves the close cooperation of the urban transportation system, communication facilities and equipment, and departments within the hospital. Each link is more likely to break and harder to implement. However, some experts believe this model closely links prehospital first aid with hospital emergencies, understands the concepts of "ten minutes platinum time" and "golden period" in the care of patients with multiple injuries, and reduces treatment time to a limit. In order to make patients with multiple injuries get the most effective treatment, several studies have shown that integrated care in the emergency time window has dramatically improved the treatment rate and survival rate of patients with multiple injuries, which is beneficial for its

promotion and implementation throughout the country.^{1,11}

Impression fractures carry a high risk of causing increased pressure on the brain and damaging the normal parenchyma due to the applied force. This force can directly damage the neurological tissue and blood vessels or indirectly cause a subdural and/or extradural hematoma to form under the skull and compress the underlying brain tissue.¹²

In the study of Prakash et al., the incidence of skull fractures was 44/100,000 people/year. Most simple skull fractures occur more than impression fractures and combined fractures. This greater rate of severe and moderate injury may be due to early neglect of the injury and poor or difficult access to medical facilities leading to delays in medical care in developing countries like ours, resulting in the conversion of minor head injuries to moderate head injuries. The higher incidence of joint fractures may result from the increased number of suspected assault/violent cases obtained. This higher and accepted force to a concentrated skull area is more likely to cause impression and joint fractures. In the case of impression, fractures can also affect and possibly tear the dura and venous sinuses. The possibility of infection also needs to be considered, such as superficial wound infections such as subdural empyema.¹³

Management of patients with skull fractures due to impressions varies according to the protocol. Most neurosurgeons in developing countries still follow the classical management method, in which if the joint injury is not cleaned, the bone fragments are removed and not replaced. If the dura mater is torn, closure for repair is sought. This operation was

followed by a cranioplasty after a few months. If the wound is clean, replace the bone fragments in the same operation. Closed impression fractures can be followed up with a conservative approach or a surgical approach depending on the impression level, the effect of the compression, or for cosmetic purposes. Impression fractures above the venous sinuses are left undisturbed and evaluated to avoid bleeding.¹³

Mortality is much higher for elderly patients who have co-existing medical illnesses and delays in seeking treatment in most cases. The provision of follow-up care for trauma patients is not available. Imaging modalities such as CT scans and MRIs are also not easily accessible. Associated intracranial lesions and higher infection rates may also account for the significant increase in mortality. The higher mortality rate in developing countries like ours worries us to develop more efficient protocols to manage cases with impression skull fractures. The need for management not only includes efforts in the hospital environment but also must aim to create awareness and strategies for individuals and communities to avoid incidents, such as strict adherence to traffic rules, better management of comorbidities, and a harmonious environment to reduce cases of violence.¹³

A conservative approach can be adopted in many cases with good outcomes. The main reason for attempting an early single-stage reconstruction of combined depressed skull fractures and multiple closed impression fractures is to provide potential benefits for functional, aesthetic, and psychological outcomes. Although there is no convincing evidence that early use of antibiotics can

prevent or reduce the risk of infection, it is advisable to debride the wound early and apply an antibiotic cover if a "dirty" wound occurs. Thus, considering the different management strategies and health care provision, a more holistic approach to treating and avoiding the incidence of skull fractures such as impression fractures can reduce mortality and morbidity significantly and have a better outcome.¹³

Contrecoup injury, a form of focal injury, is well known. There are very few studies on contrecoup injuries, and their clinical significance and outcomes in this subgroup of head injury patients are largely unknown. The biomechanics of contrecoup injury is explained by shock wave theory. Shock wave theory that starts at the point of impact and spreads through the brain can be reflected from the opposite side of the skull and reverberate within the brain. A contrecoup injury indicates that the continued traumatic force is transmitted to the brain. This biomechanism explains that the brain may have suffered more damage than the usual brain injury without a counter-coup.¹⁴ In this case, the mechanism of injury of the patient's head hit the chair and the pillar of the driver's car. Moreover, the patient has an accident because the force from the opposite direction with the trauma force is tremendous, so there will be a counter-coup trauma. Patients with closed rotational or accelerated-deceleration head injuries should be suspected of having DAI.

The degree of a contrecoup brain injury determines how it should be treated. For lesions that do not require immediate surgical decompression, close clinical surveillance with a follow-up head CT at 12 or 24 hours is recommended. Some individuals with impair-

ed neurologic status and a Glasgow coma rating of 8 or lower need get trauma-specific care and intracranial pressure monitoring.¹⁶ Depending on the neurologic examination and the type and size of the injury, some patients will require surgery. Interventions may be for hematoma drainage only but may be more extensive to involve lobectomy and/or decompressive hemicraniectomy. According to the guidelines, the patient will require anti-epileptic drugs for seven days. Contrecoup brain injury is one of the manifestations of traumatic brain injury and should be integrated with other types of brain injury and multiple-body trauma.

In general, DAI is a severe form of traumatic brain injury. Therefore, adopting advanced trauma life support protocols is the standard of care for all head injury patients. The definitive diagnosis of DAI can be made in a postmortem pathological examination of brain tissue. In contrast, clinical data and radiographic results are applied in clinical practice to make the diagnosis of diffuse axonal damage. The differential diagnosis of DAI is made easier by knowing how head injuries occur. DAI is typically identified after a traumatic brain injury in patients with a GCS of less than 8 for more than six continuous hours.¹⁷

Radiographically, computed tomography (CT) findings of the head revealing small hemorrhages (petechiae) into the gray matter area may suggest diffuse axonal injury in an appropriate clinical presentation. Overall, head CT has poor results in detecting injuries associated with diffuse axonal injury. Magnetic resonance imaging (MRI), particularly diffuse tensor imaging (DTI), is the imaging modality of choice for diagnosing diffuse axonal injury.

A recent report showed that an acute gradient-recall echo (GRD) MRI would improve the detection of axonal injury in grade 3 diffuse axonal injury patients, suggesting that it is likely a better diagnostic tool.¹⁸

It should be noted that DAI should be strongly considered in patients who fail to improve after surgical evacuation of a subdural or epidural hematoma. Conversely, DAI may be absent if the patient drastically improves after surgical evacuation of a subdural or epidural hematoma. The care of patients with diffuse axonal injury is directed toward preventing secondary injury and facilitating rehabilitation. It appears that secondary injuries are causing an increase in mortality. These can include hypoxia with accompanying hypotension, edema, and intracranial hypertension. Therefore, prompt treatment to avoid hypotension, hypoxia, cerebral edema, and increased intracranial pressure (ICP) is advised.

The initial treatment priority in traumatic brain injury is focused on resuscitation. In non-neurotrauma centers, trauma surgeons and emergency physicians can perform initial resuscitation and neurologic care to stabilize and transfer patients to designated neurotrauma centers as quickly as possible. ICP monitoring is indicated in patients with a GCS of less than eight after consultation with neurosurgeons. Other considerations for ICP monitoring include patients who cannot have ongoing neurologic evaluation. The majority of patients who suffer from this syndrome are those who are receiving general anesthesia, opioid analgesics, sedation, and protracted paralysis for other ailments. ICP monitoring and cerebral oxygen saturation monitoring can be used to determine the level of oxygenation.

Early post-traumatic seizures can be avoided by a short-term anticonvulsant regimen, typically seven days. However, there is no proof to suggest that doing so can stop long-term post-traumatic seizures. Evidence suggests that progesterone treatment in acute traumatic brain injury can reduce morbidity and mortality. It cannot be routinely recommended at this time. Overall, treatment goals for patients with diffuse axonal injury are supportive care and prevention of secondary injury.

An open fracture is one of the emergencies in the orthopedic field. External fixation is a widely used method for treating open fractures of the tibia, as it is considered to have a low incidence of infection. It does not require device placement at the fracture site and is characterized by a lower risk of vascular damage. External fixation can also be used as definitive or temporary fixation. External fixation allows using multi-planar mounts—with medial and lateral rods attached with screws or pins—in a rectangular, triangular, or other specified configuration, depending on which method provides the best stability²⁰.

Circular external fixator and hybrid fixator show complexity highest configuration. Circular fixators consist of a complete or half ring attached to the tibia with a tightened thread. The hybrid fixator consists of a two-ring system with threaded threads and bolts with screws.²¹

Intramedullary locking nails are the gold standard for treating closed and unstable tibial shaft fractures and open fractures (Gustilo-Anderson types I, II, and III A). Many studies have reported a high percentage of consolidation and a low incidence of erroneous

consolidation and infection, even in the case of open fractures. If there is any doubt about the possibility of treating a fracture of the tibia shaft with an intramedullary nail, it is possible to start the initial treatment with an external one.

CONCLUSION

For now, there are several problems in patient care with multiple trauma in most of our country, like a flawed primary survey before hospitality and the information in the hospital, the weakness of comprehensive care, and so on. There is no integrated model for caring for patients with multiple trauma, compared to the traditional, triage, and integrated trauma care modes.

Trauma centers dominate the multidisciplinary assisted treatment model. The emergency department independently treats most patients with multiple injuries under surgery and postoperative monitoring because of its emphasis on the continuity chain of treatment and survival. This management was gradually appreciated and accepted by most doctors. However, implementing a multidisciplinary mentoring and treatment model led by a trauma center needs to be established in specific areas according to the region's characteristics, region, population, road status, and level of medical resources. Each region can choose according to its actual situation. Moreover, even develop their treatment model.

REFERENCES

1. Xiao, X. & Ke, D. Advances in Diagnosis and Treatment of Multiple Injuries. *SOJ Surg.* **6**, 1–5 (2019).
2. Frink, M., Lechler, P., Debus, F. & Ruchholtz, S. Multiple Trauma and Emergency Room Management. *Dtsch. Arztebl. Int.* **114**, 497–503 (2017).
3. Pape, H.-C. *et al.* The definition of polytrauma revisited: An international consensus process and proposal of the new 'Berlin definition'. *J. Trauma Acute Care Surg.* **77**, 780–786 (2014).
4. Zong, Z.-W. *et al.* Chinese expert consensus on echelons treatment of thoracic injury in modern warfare. *Mil. Med. Res.* **5**, 34 (2018).
5. Saadat, S., Akbari, H., Khorramirouz, R., Mofid, R. & Rahimi-Movaghar, V. Determinants of mortality in patients with traumatic brain injury. *Ulus. travma ve acil cerrahi Derg. = Turkish J. trauma Emerg. TJTES* **18**, 219–224 (2012).
6. Akhavan Akbari, G. & Mohammadian, A. Comparison of the RTS and ISS scores on prediction of survival chances in multiple trauma patients. *Acta Chir. Orthop. Traumatol. Cech.* **79**, 535–539 (2012).
7. Domingues, C. de A., Coimbra, R., Poggetti, R. S., Nogueira, L. de S. & de Sousa, R. M. C. New Trauma and Injury Severity Score (TRISS) adjustments for survival prediction. *World J. Emerg. Surg.* **13**, 1–6 (2018).
8. Carroll, C. P., Cochran, J. A., Price, J. P., Guse, C. E. & Wang, M. C. The AIS-2005 Revision in Severe Traumatic Brain Injury: Mission Accomplished or Problems for Future Research? *Ann. Adv. Automot. Med. Assoc. Adv. Automot. Med. Annu. Sci. Conf.* **54**, 233–238 (2010).

9. Jiang, B. *et al.* Transport and public health in China: the road to a healthy future. *Lancet (London, England)* **390**, 1781–1791 (2017).
10. Zafar, S. N. *et al.* Road traffic injuries: Cross-sectional cluster randomized countrywide population data from 4 low-income countries. *Int. J. Surg.* **52**, 237–242 (2018).
11. Daban, J., Falzone, E., Boutonnet, M., Peigne, V. & Lenoir, B. [Wounded in action: the platinum ten minutes and the golden hour]. *Soins.* 14–15 (2014).
12. Manne, S. *et al.* Surgical Outcomes in Depressed Skull Fractures: An Institutional Experience. *Asian J. Neurosurg.* **14**, 815–820 (2019).
13. Prakash, A., Harsh, V., Gupta, U., Kumar, J. & Kumar, A. Depressed Fractures of Skull: An Institutional Series of 453 Patients and Brief Review of Literature. *Asian J. Neurosurg.* **13**, 222–226 (2018).
14. Payne, W. N., De Jesus, O. & Payne, A. N. Contrecoup Brain Injury. in (2022).
15. van Eijck, M. M., Schoonman, G. G., van der Naalt, J., de Vries, J. & Roks, G. Diffuse axonal injury after traumatic brain injury is a prognostic factor for functional outcome: a systematic review and meta-analysis. *Brain Inj.* **32**, 395–402 (2018).
16. Carney, N. *et al.* Guidelines for the Management of Severe Traumatic Brain Injury, Fourth Edition. *Neurosurgery* **80**, 6–15 (2017).
17. Davceva, N., Sivevski, A. & Basheska, N. Traumatic axonal injury, a clinical-pathological correlation. *J. Forensic Leg. Med.* **48**, 35–40 (2017).
18. Ottens, A. K. *et al.* Post-acute brain injury urinary signature: a new resource for molecular diagnostics. *J. Neurotrauma* **31**, 782–788 (2014).
19. Mesfin, F. B., Gupta, N., Shapshak, A. H. & Taylor, R. S. Diffuse Axonal Injury. *StatPearls [Internet]. Treasure Isl. StatPearls Publ.* (2022).
20. Socie, M. J. *et al.* Biomechanical comparison of strategies to adjust axial stiffness of a hybrid fixator. *Vet. Comp. Orthop. Traumatol.* **25**, 224–230 (2012).
21. ILIZAROV, G. A. & LEDYAEV, V. I. The Replacement of Long Tubular Bone Defects by Lengthening Distraction Osteotomy of One of the Fragments. *Clin. Orthop. Relat. Res.* **280**, (1992).
22. Henley, M. B. *et al.* Treatment of type II, IIIA, and IIIB open fractures of the tibial shaft: a prospective comparison of unreamed interlocking intramedullary nails and half-pin external fixators. *J. Orthop. Trauma* **12**, 1–7 (1998).